TRATAMIENTO QUIRURGICO DE LA ENDOMETRIOSIS

MARTHA PATRICIA TORRES POLANCO
RESIDENTE GO FUSM. 2010

ENDOMETRIOSIS

- Von Rokitansky 1860
- Enfermedad enigmática

ROCK JOHN. Endometriosis. Ginecología Quirúrgica. TE LINDE. Novena Edición. Tomo I, capitulo 25. pág.. 645-684.

DEFINICION

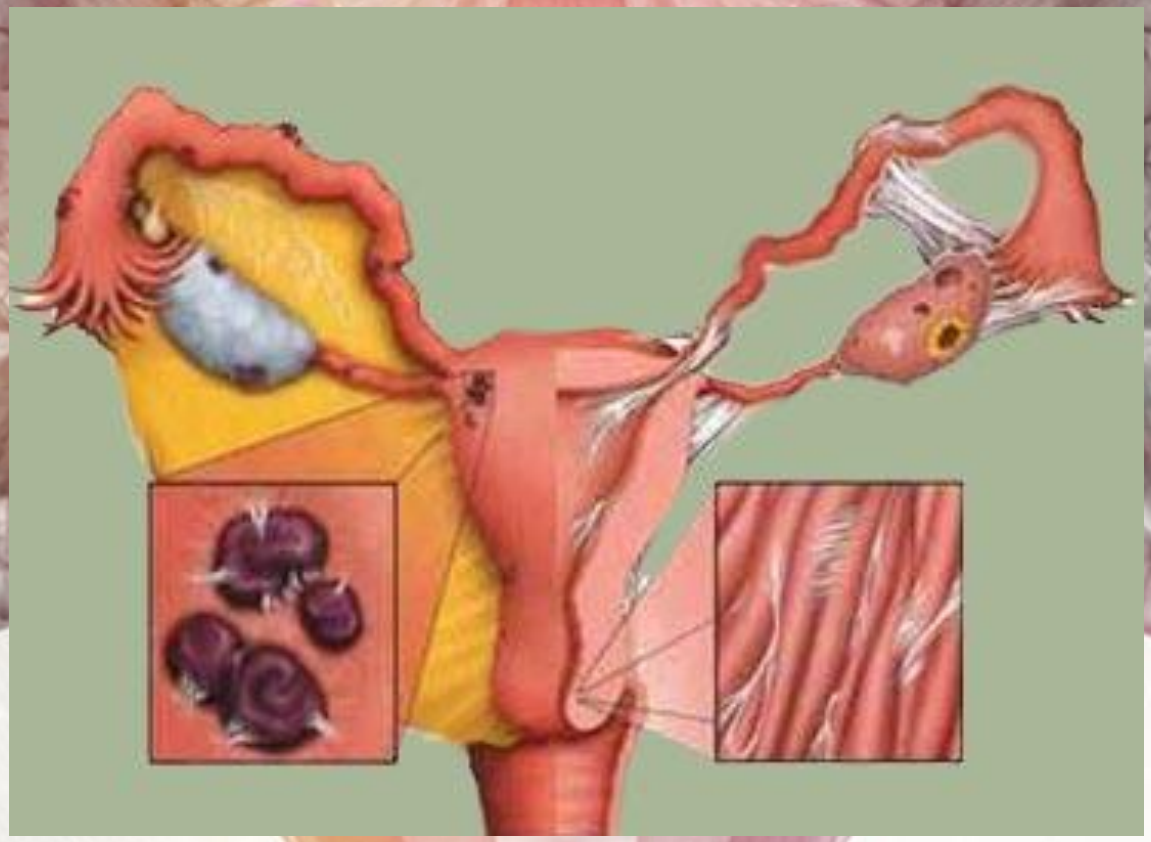

PEREZ LUIS ERNESTO. Infertilidad y Endocrinología Reproductiva. Endometriosis. Segunda Edición. Capítulo 10. 2000.

- En respuesta hormonal
- En apariencia visual
- En ultraestructura

PEREZ LUIS ERNESTO. Infertilidad y Endocrinología Reproductiva. Endometriosis. Segunda Edición. Capítulo 10. 2000.

CLINICAL OBSTETRICS AND GYNECOLOGY
Volume 53, Number 2, 389–396
© 2010, Lippincott Williams & Wilkins

Epidemiology of Endometriosis: An Assessment of Risk Factors

BRANDI S. MCLEOD, MD and
MATTHEW G. RETZLOFF, MD

Department of Obstetrics and Gynecology, Wilford Hall Medical Center, SAUSHEC, Lackland Air Force Base, Texas

PREVALENCIA

- 10% (5-40%) Edad reproductiva
- 20-40% Mujeres estériles
- Edad
- Raza
- Historia familiar (6.9%)
- Anomalías anatómicas

- Variante Genética

- Cromosoma 7
- Cromosoma 1, gen WNT4

- investigación realizada por investigadores de la Universidad de Oxford (el Departamento de Obstetricia y Ginecología de Nuffield y el Centro de Genética Humana Wellcome Trust) y del Instituto de Investigación Médica de Queenslandel Brigham and Women's Hospital

LOCALIZACION

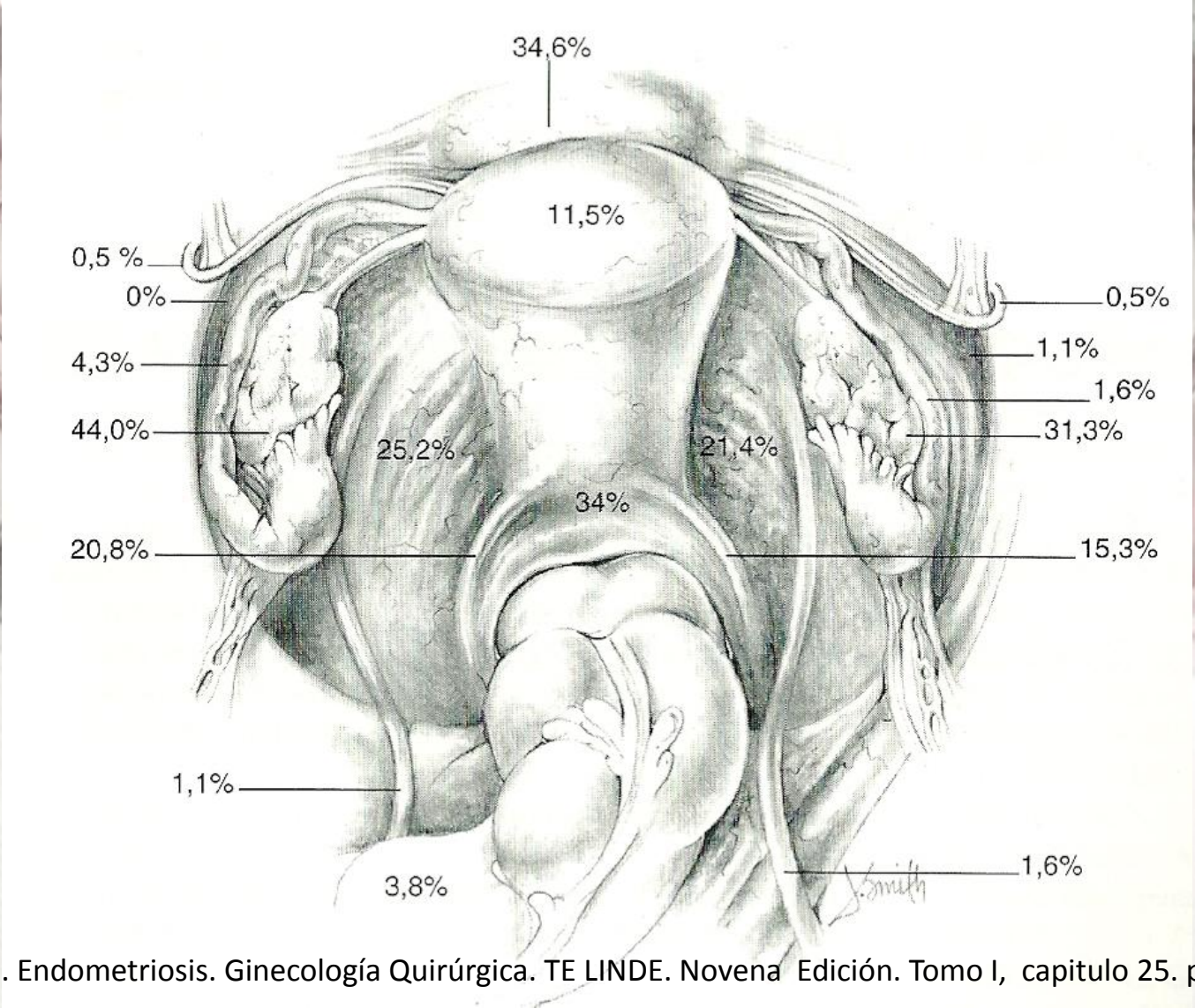

ROCK JOHN. Endometriosis. Ginecología Quirúrgica. TE LINDE. Novena Edición. Tomo I, capitulo 25. pág.. 645-684.

HISTOGENESIS

CLINICAL OBSTETRICS AND GYNECOLOGY
Volume 53, Number 2, 379–388
© *2010, Lippincott Williams & Wilkins*

Evolving Spectrum: The Pathogenesis of Endometriosis

JANI R. JENSEN, MD and
CHARLES C. CODDINGTON, III, MD

TEORIA DEL REFLUJO Y EL IMPLANTE DIRECTO

- SAMPSON

TEORIA DE LA METAPLASIA CELOMICA TEORIA DE MEYER, (Iwanoff,1898)

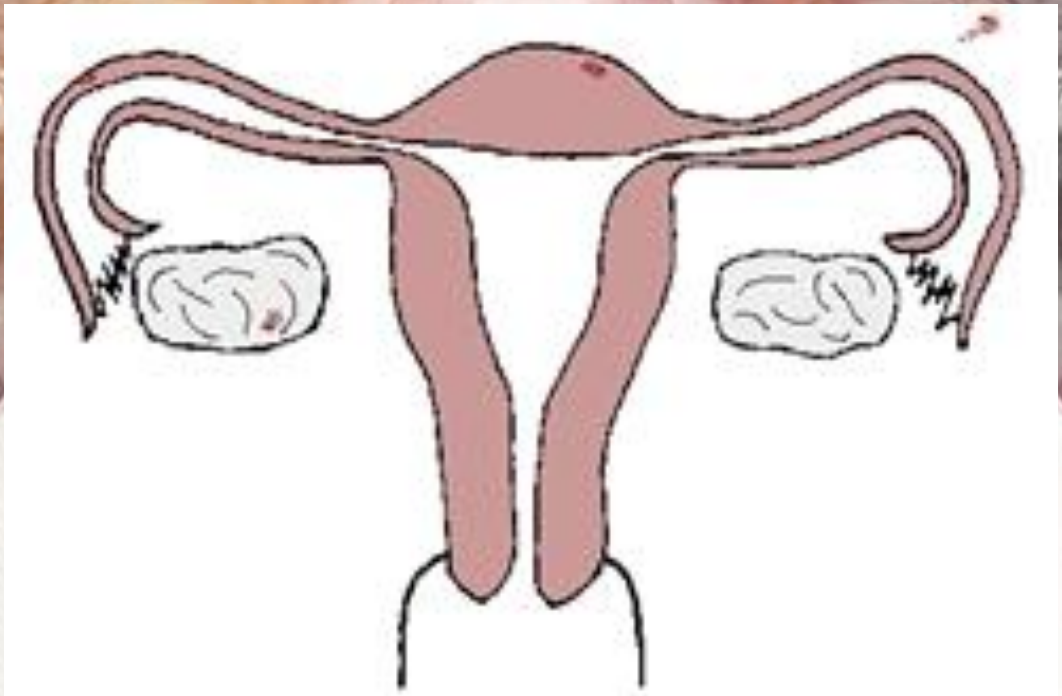

TEORIA DE LA DISEMINACION VASCULAR
TEORIA DE HALBAN

TEORIA DE LA ENFERMEDAD AUTOINMUNE

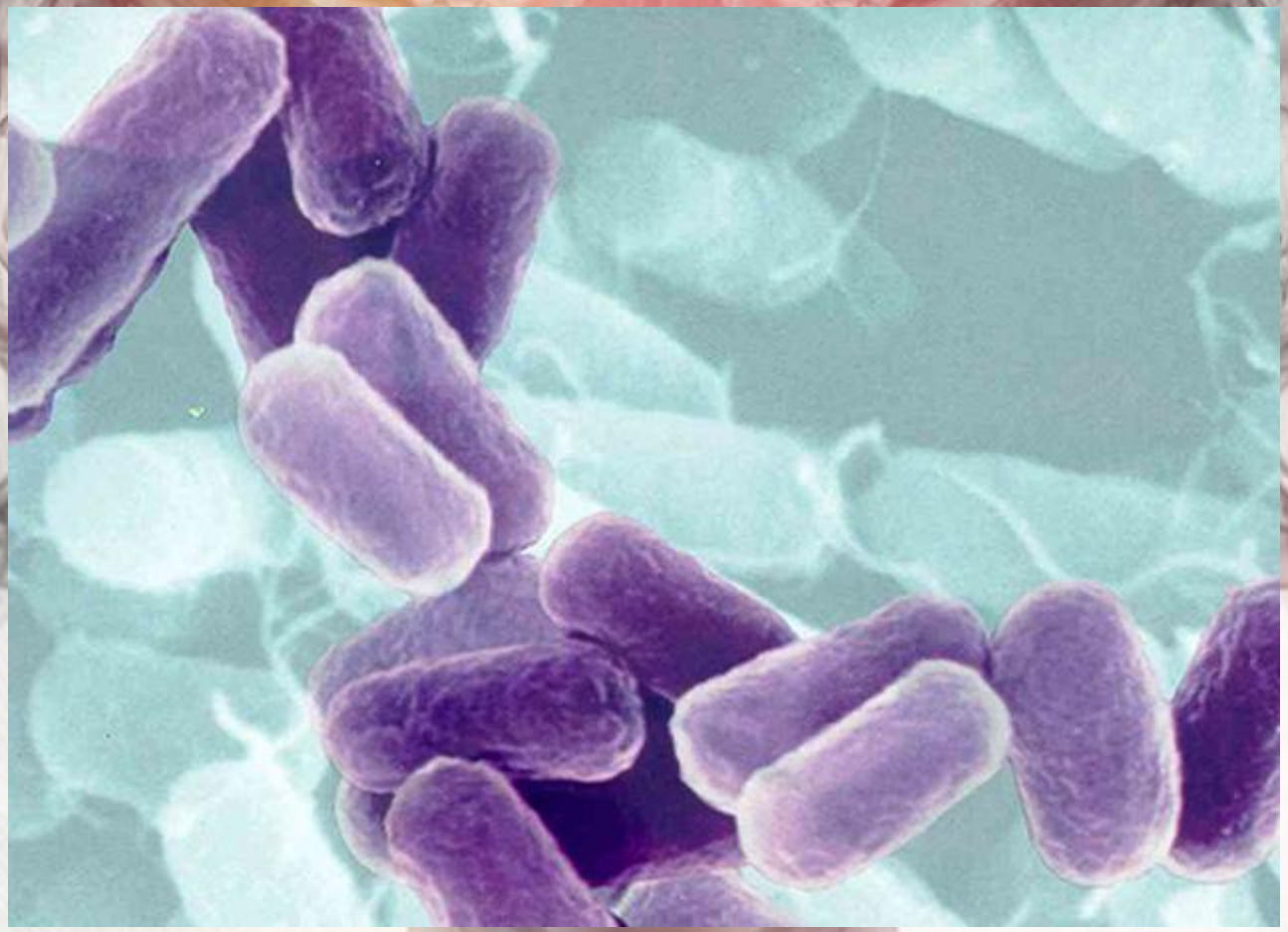

FACTORES PROMOTORES

- Estrógeno dependiente
- Nivel socio económico alto
- Herencia
- Inflamaciones
- Iatrogenia
- Embarazo
- Menopausia
- ACOs

PEREZ LUIS ERNESTO. Infertilidad y Endocrinología Reproductiva. Endometriosis. Segunda Edición. Capítulo 10. 2000.

TABLE 1

Risk Factors for Endometriosis

Risk factor/comparison	*Odds ratio*	*95% confidence interval*
Mother or sister has endometriosis/mother and sister do not have endometriosis	7.2	2.1 to 24.3[6]
Menstrual flow six days or more/flow less than six days	2.5	1.1 to 5.9[7]
Menstrual cycle less than 28 days/cycle of 28 to 34 days	2.1	1.5 to 2.9[8]
Consuming one or more alcoholic drinks per week/no alcohol consumption	1.8	1.0 to 3.2[9]
Never used OCPs/ever used OCPs	1.6	1.2 to 2.2[10]
Use of pads and tampons/use of either pads or tampons	1.4	0.9 to 2.0[2]

OCPs = oral contraceptive pills.

Information from references 2 and 6 through 10.

Downloaded from the American Family Physician Web site at www.aafp.org/afp. Copyright © 2006 American Academy of Family Physicians. For the private, noncommerci use of one individual user of the Web site. All other rights reserved. Contact copyrights@aafp.org for copyright questions and/or permission requests.

TIPOS DE IMPLANTES

- PERITONEALES

1. IMPLATES ROJOS

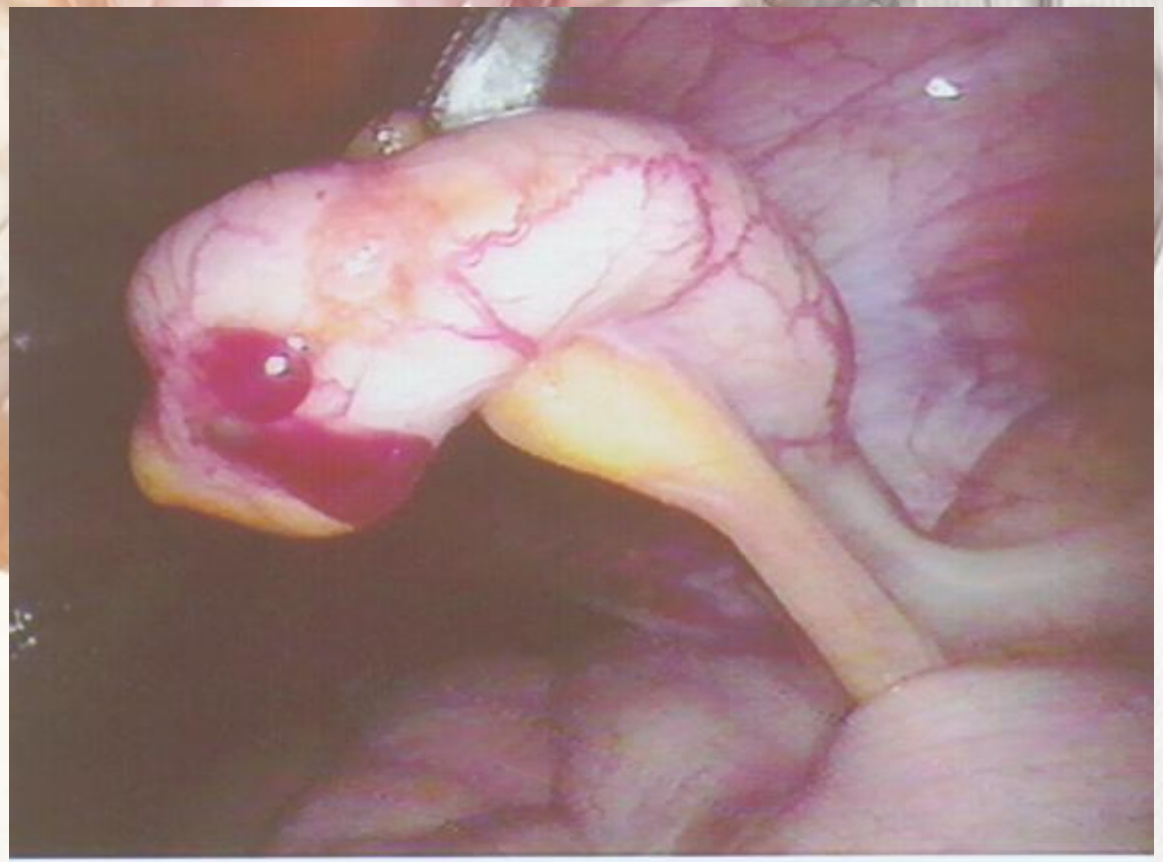

- IMPLANTES NEGROS

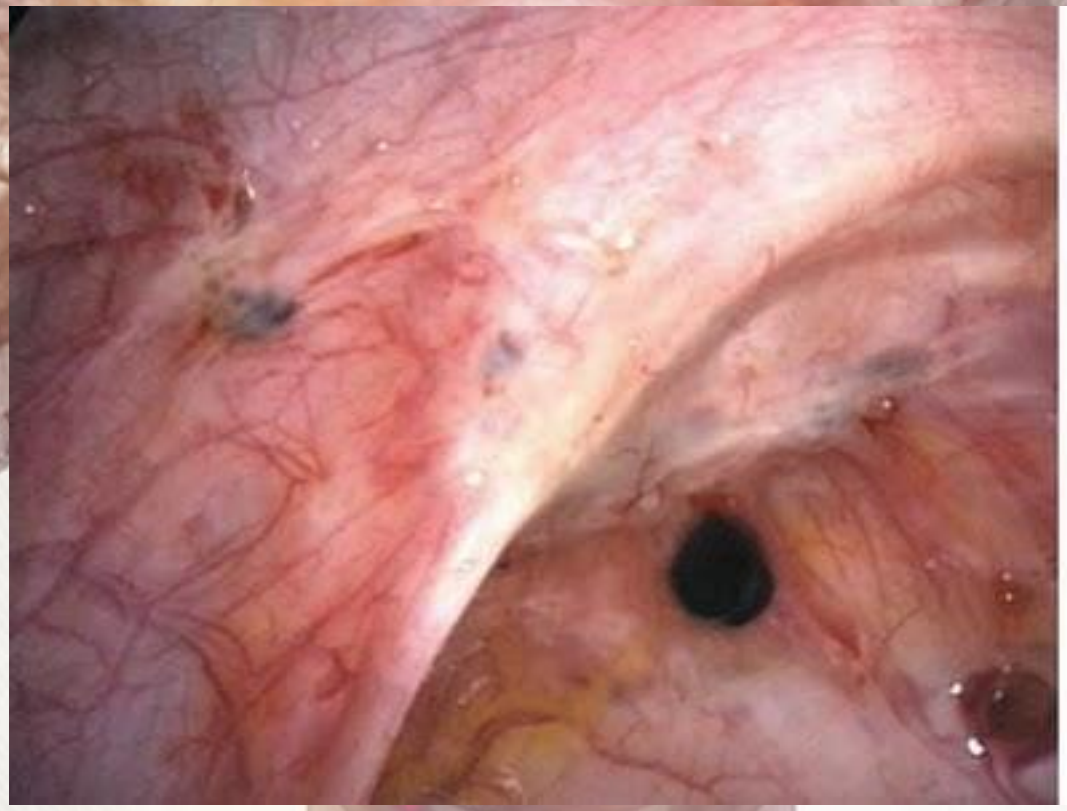

- IMPLANTES BLANCOS

IMPLANTES PROFUNDOS

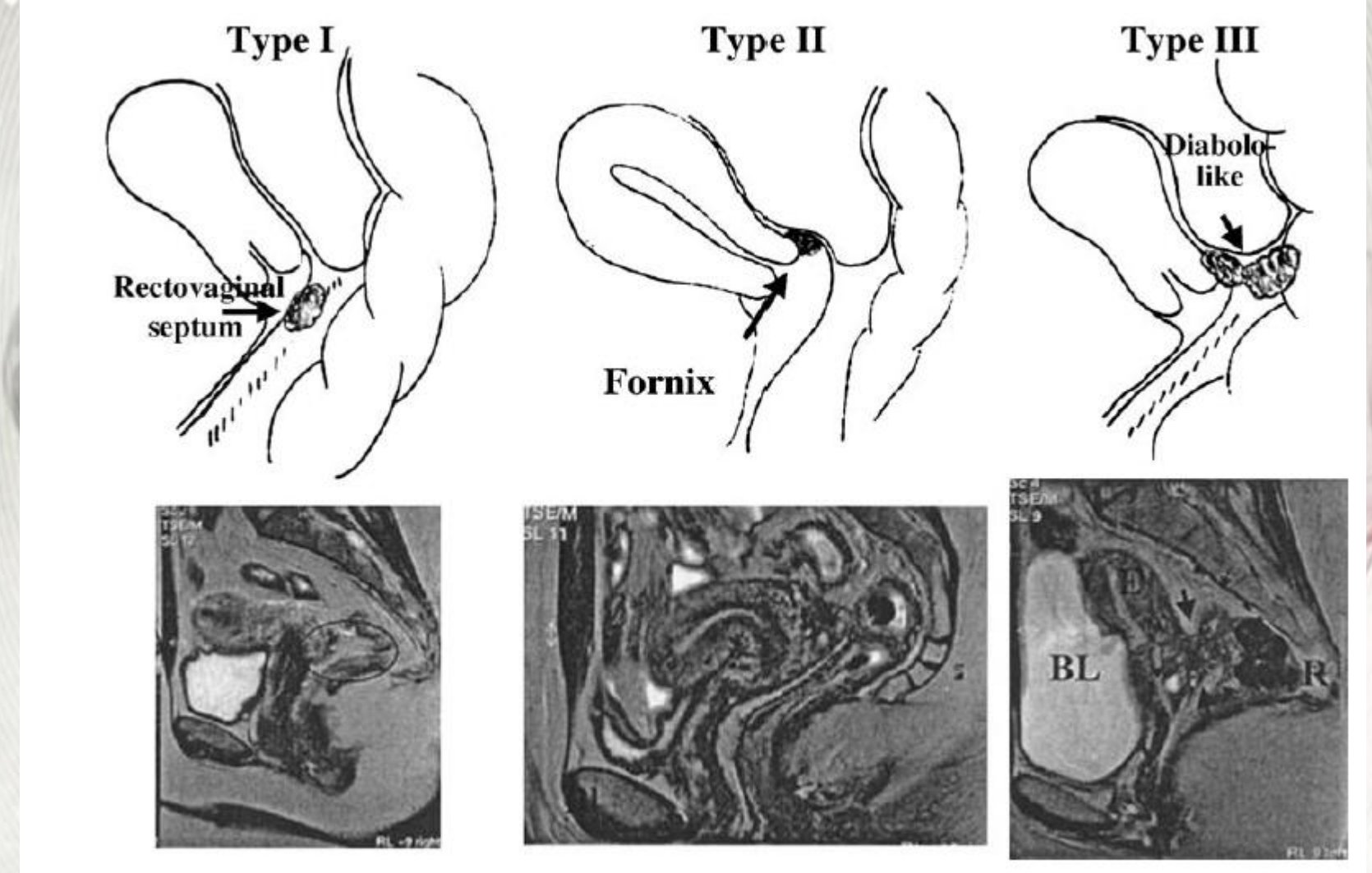

ENDOMETRIOMAS

- Quistes ovaricos de Sampson

- Características:

- < 12 cm
- Adherencias a pared pélvica
- Superficie ovárica
- Liquido achocolatado

PEREZ LUIS ERNESTO. Infertilidad y Endocrinología Reproductiva. Endometriosis. Segunda Edición. Capítulo 10. 2000.

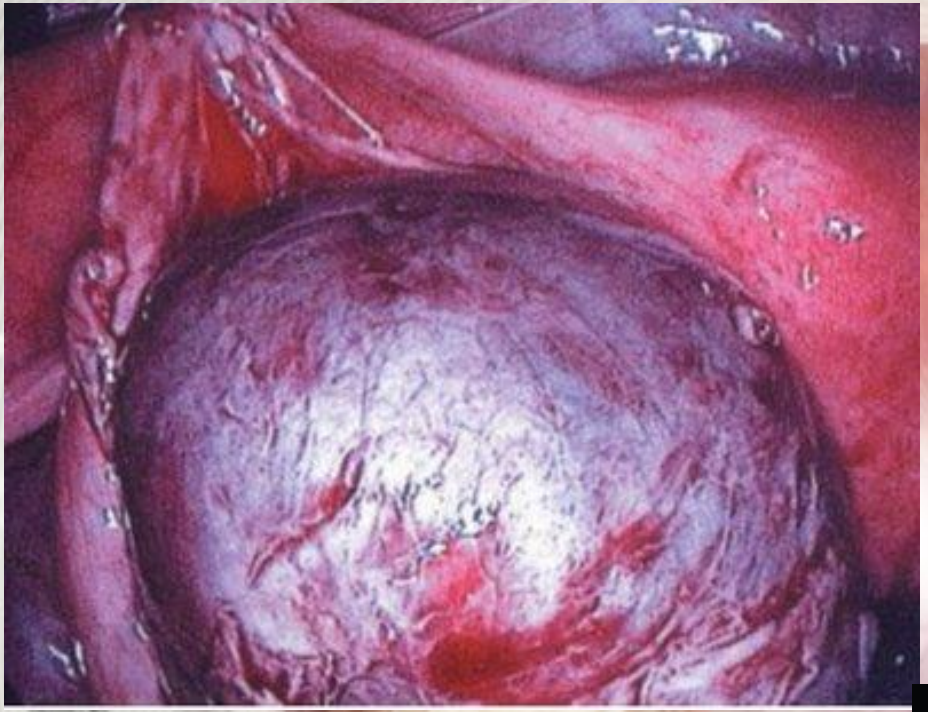

DIAGNOSTICO

- SINTOMAS

SINTOMAS	%
DISMENORREA	60-80%
DOLOR PELVICO	30-50%
INFERTILIDAD	30-40%
DISPAREUNIA	25-40%
IRREGULARIDAD MENSTRUAL	10-20%
DISURIA/HEMATURIA	1-2%
DISQUESIA, RECTORRAGIA	<1%

PEREZ LUIS ERNESTO. Infertilidad y Endocrinología Reproductiva. Endometriosis. Segunda Edición. Capítulo 10. 2000.

- SIGNOS

- Engrosamiento y nodularidad de uterosacros
-Engrosamiento de parametrios
- Masas anexiales
- Retroversoflexion
- Lesiones endometriosicas

CLINICAL OBSTETRICS AND GYNECOLOGY
Volume 53, Number 2, 413–419
© 2010, Lippincott Williams & Wilkins

Invasive and Noninvasive Methods for the Diagnosis of Endometriosis

ALBERT L. HSU, MD, IZABELLA KHACHIKYAN, MD, and PAMELA STRATTON, MD

Program in Reproductive and Adult Endocrinology, Eunice Kennedy Shriver National Institute of Child Health and Human Development, National Institutes of Health, Bethesda, Maryland

- LAPAROSCOPIA
- BIOPSIA
- IMAGENOLOGIA
- CITOLOGIA POR ASPIRACION
- CA 125
- PROTEINA PP 14 Y AC ANTIENDOMETRIO
- IL-6 (2 pg / ml)

Laparoscopía: La inspección visual de la pelvis es el “gold standard” en el diagnóstico y clasificación de la endometriosis pelviana

Diagnosis

C	For a definitive diagnosis of endometriosis, visual inspection of the pelvis at laparoscopy is the ‘gold standard’ investigation, unless disease is visible in the vagina or elsewhere.	Evidence level 3

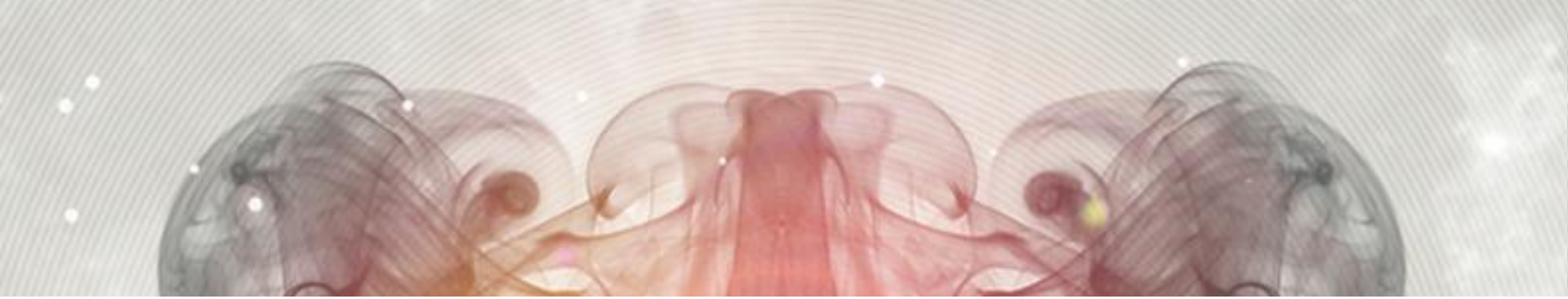

Human Reproduction Vol.20, No.10 pp. 2698–2704, 2005 doi:10.1093/humrep/dei135
Advance Access publication June 24, 2005.

ESHRE guideline for the diagnosis and treatment of endometriosis

Stephen Kennedy[1,10], Agneta Bergqvist[2], Charles Chapron[3], Thomas D'Hooghe[4], Gerard Dunselman[5], Robert Greb[6], Lone Hummelshoj[7], Andrew Prentice[8] and Ertan Saridogan[9] on behalf of the ESHRE Special Interest Group for Endometriosis and Endometrium Guideline Development Group*

Laparoscopy

GPP	Good surgical practice is to document in detail the type, location and extent of all lesions and adhesions in the operative notes; ideal practice is to record the findings on video or DVD.	
GPP	There is insufficient evidence to justify timing the laparoscopy at a specific time in the menstrual cycle, but it should not be performed during or within 3 months of hormonal treatment so as to avoid under-diagnosis.	
C	All classification systems for endometriosis are subjective and correlate poorly with pain symptoms, but may be of value in infertility prognosis and management (Chapron *et al.*, 2003b; D'Hooghe *et al.*, 2003).	Evidence level 3
C	At laparoscopy, deeply infiltrating endometriosis may have the appearance of minimal disease, resulting in an underestimation of disease severity (Koninckx *et al.*, 1994).	Evidence level 3

Investigations

Ultrasound

A	Compared to laparoscopy, transvaginal ultrasound (TVS) has no value in diagnosing peritoneal endometriosis, but it is a useful tool both to make and to exclude the diagnosis of an ovarian endometrioma (Moore *et al.*, 2002). TVS may have a role in the diagnosis of disease involving the bladder or rectum.	Systematic review of diagnostic tests

Magnetic resonance imaging

A	Compared to laparoscopy, magnetic resonance imaging (MRI) has limited value as a diagnostic tool for endometriosis (Ang *et al.*, submitted).	Systematic review of diagnostic tests

Blood tests

A	Serum CA-125 levels may be elevated in endometriosis. However, compared to laparoscopy, measuring serum CA-125 levels has no value as a diagnostic tool (Mol *et al.*, 1998).	Systematic review of diagnostic tests

CLASIFICACION

THE AMERICAN FERTILITY SOCIETY
CLASIFICACION REVISADA DE LA ENDOMETRIOSIS

Nombre del Paciente _____ Fecha _____

Estadio I (Minimo) - 1-5
Estadio II (Leve) - 6-15
Estadio III (Moderado) - 16-40
Estadio IV (Severo) - >40

Total _____

Laparoscopia _____ Laparotomía _____ Fotografía _____

Tratamiento Recomendado _____

Pronóstico _____

	ENDOMETRIOSIS		<1cm	1-3cm	>3cm
PERITONEO		Superficial	1	2	4
		Profunda	2	4	6
OVARIO	D	Superficial	1	2	4
		Profunda	4	16	20
	I	Superficial	1	2	4
		Profunda	4	16	20

	OBLITERACION DEL FONDO DE SACO POSTERIOR	Parcial	Completa
		4	40

	ADHERENCIAS		Comprometido <1/3	Comprometido 1/3-2/3	Comprometido >2/3
OVARIO	D	Delgada	1	2	4
		Densa	4	8	16
	I	Delgada	1	2	4
		Densa	4	8	16
TROMPA	D	Delgada	1	2	4
		Densa	4*	8*	16
	I	Delgada	1	2	4
		Densa	4*	8*	16

***Si el extremo distal de la trompa (fimbria) esta comprometido completamente, asigne un puntaje de 16.**

ESTADIOS AFS

- Estadio I (mínimo) : 1-5
- Estadio II (leve) : 6-15
- Estadio III (moderado): 16-40
- Estadio IV (severo) : > 40

STAGE I (MINIMAL)

PERITONEUM			
Superficial Endo	–	1-3cm	-2
R. OVARY			
Superficial Endo	–	< 1cm	-1
Filmy Adhesions	–	< 1/3	-1
TOTAL POINTS			4

STAGE II (MILD)

PERITONEUM			
Deep Endo	–	> 3cm	-6
R. OVARY			
Superficial Endo	–	< 1cm	-1
Filmy Adhesions	–	< 1/3	-1
L. OVARY			
Superficial Endo	–	< 1cm	-1
TOTAL POINTS			9

STAGE III (MODERATE)

PERITONEUM			
Deep Endo	–	> 3cm	-6
CULDESAC			
Partial Obliteration			-4
L. OVARY			
Deep Endo	–	1-3cm	-16
TOTAL POINTS			26

STAGE III (MODERATE)

PERITONEUM			
Superficial Endo	–	> 3cm	-4
R. TUBE			
Filmy Adhesions	–	< 1/3	-1
R. OVARY			
Filmy Adhesions	–	< 1/3	-1
L. Tube			
Dense Adhesions	–	< 1/3	-16*
L. OVARY			
Deep Endo	–	< 1cm	-4
Dense Adhesions	–	< 1/3	-4
TOTAL POINTS			30

STAGE IV (SEVERE)

PERITONEUM			
Superficial Endo	–	> 3cm	-4
L. OVARY			
Deep Endo	–	1-3cm	-32**
Dense Adhesions	–	< 1/3	-8**
L. Tube			
Dense Adhesions	–	< 1/3	-8**
TOTAL POINTS			52

*Point assignment changed to 16
**Point assignment doubled

STAGE IV (SEVERE)

PERITONEUM			
Deep Endo	–	> 3cm	-6
CULDESAC			
Complete Obliteration			-40
R. OVARY			
Deep Endo		1-3cm	-16
Dense Adhesions	–	< 1/3	-4
L. Tube			
Dense Adhesions	–	> 2/3	-16
L. OVARY			
Deep Endo	–	1-3cm	-16
Dense Adhesions	–	> 2/3	-16
TOTAL POINTS			114

TRATAMIENTO

FERTILITY AND STERILITY®
VOL. 78, NO. 5, NOVEMBER 2002
Copyright ©2002 American Society for Reproductive Medicine
Published by Elsevier Science Inc.
Printed on acid-free paper in U.S.A.

ENDOMETRIOSIS

Consensus statement for the management of chronic pelvic pain and endometriosis: proceedings of an expert-panel consensus process

Joseph C. Gambone, D.O., M.P.H.,[a,b] Brian S. Mittman, Ph.D.,[b,c] Malcolm G. Munro, M.D.,[a] Anthony R. Scialli, M.D.,[d] Craig A. Winkel, M.D., M.B.A.,[d] and the Chronic Pelvic Pain/Endometriosis Working Group

UCLA Medical School, Los Angeles, California

CLINICAL OBSTETRICS AND GYNECOLOGY
Volume 52, Number 3, 351–361
© 2009, Lippincott Williams & Wilkins

Laparoscopic Surgery for Endometriosis

MICHELLE CATENACCI, MD, SUCHETHA SASTRY, MD, and TOMMASO FALCONE, MD

The Cleveland Clinic, Department of Obstetrics and Gynecology, Cleveland, Ohio

LINEAS DE TRATAMIENTO

- Expectante
- Médico
- Hormonal
- **QUIRURGICO**

TRATAMIENTO

- Corregir dolor
- Esterilidad
- Síntomas en endometriosis extensa
- Falla manejo médico

- Reconocimiento de objetivos
  - Manejo del dolor
  - Restauración/preservación de la fertilidad
- Discutir con el paciente
  - La enfermedad es crónica e incurable
  - Tratamiento óptimo no probado o no existente

INDICACIONES PARA EL TRATAMIENTO HORMONAL

- Lesiones endometriòsicas pequeñas
- Recurrencia después de cirugía conservadora
- Preoperatorio 6-12 semanas para disminuir tamaño
- Postoperatorio para lesiones residuales
- Cuando la operación esta contraindicada o es rehusada por la paciente

MEJOR TRATAMIENTO

- Los bloqueos mecánicos adherenciales, ni la endometriosis profunda responden al tratamiento médico

- El tratamiento médico solo produce regresión parcial de implantes y de su actividad, sin importar el tiempo de duración

- Recidivas de solo 5-10% con cirugía vs 30-50% con medico.

LAPAROSCOPIA

- Finalidad, resecar todas las lesiones endometriosicas visibles, las adherencias acompañantes y restaurar la anatomía normal

Double-optic laparoscopy. Salpingodcopy, ovarian cystoscop, and endovariun srgery with the argon laser. Broseins LA. Baillieris. Clin Obste. Gynecol.1989; 3:595-608

- Coagulación bipolar.
- Láser CO2 (lesión térmica mínima).
- Láser de K, Titanio y Fosfato.
- Láser de Argón.
- Ultra frecuencia.

Double-optic laparoscopy. Salpingodcopy, ovarian cystoscop, and endovariun srgery with the argon laser. Broseins LA. Baillieris. Clin Obste. Gynecol.1989; 3:595-608

Laparoscopic Views

Two chocolate cysts on the right ovary.

Dark lesions of endometriosis. These have been called blue-black lesions, gunpowder burns, and gunmetal lesions.

Red and purple raspberry spot on the left uterosacral ligament.

Soft fluffy fimbria of a normal left fallopian tube.



FOTODINAMIA

- FENESTRACION
- ESCISIÒN

Double-optic laparoscopy.Salpingodcopy,ovarian cystoscop,and endovariun srgery with the argon laser.BroseinsLA.Baillieris.ClinObste.Gynecol.1989; 3:595-608

LESIONES OVARICAS

- Superficiales se pueden vaporizar.
- Lesiones pequeñas (< de 3 cm), se aspiran, lavan y las lesiones intraquísticas se inspeccionan mediante cistoscopia ovárica.
- Lesiones grandes (> de 3 cm), se aspiran y luego se efectuará incisión y resección de la pared del quiste desde la corteza ovárica.

Double-optic laparoscopy.Salpingodcopy,ovarian cystoscop,and endovariun srgery with the argon laser.BroseinsLA.Baillieris.ClinObste.Gynecol.1989; 3:595-608

Cochrane Review (agosto 2002): resultados de la cirugía laparoscópica, en endometriosis asociada con infertilidad:

- Iguales resultados
- Hidrodisecciòn

- El ensayo más grande (Marcoux 1997), apoya claramente el incremento en la tasa de embarazo post tratamiento(R.R. 1.95, 95% CI 1.18 de 3.32).

- Cochrane: La cirugía laparoscópica, puede mejorar las tasa de embarazo (50-60%), pero los estudios no son suficientes para avalar resultados concretos

- Ensayo controlado aleatorio: La cistectomía laparoscópica ha demostrado reducir el dolor pelvico y prevenir la recurrencia más que drenaje laparoscópico solo.

- la cirugía por escisión parece ser más efectiva que el drenaje y la ablación en la prevención de la recurrencia de endometriomas y en la reducción del dolor pélvico y dispareunia

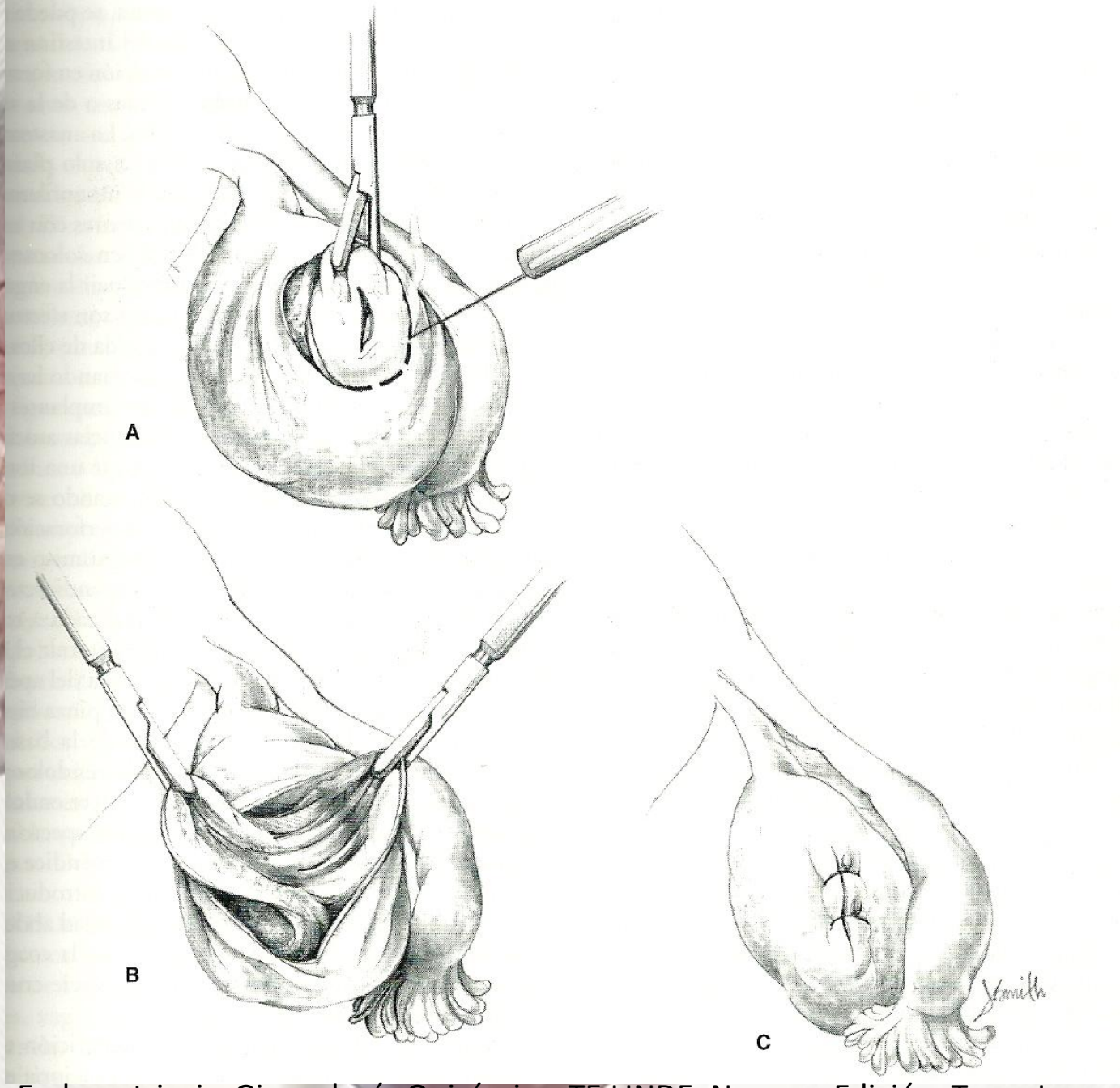

ROCK JOHN. Endometriosis. Ginecología Quirúrgica. TE LINDE. Novena Edición. Tomo I, capitulo 25. pág.. 645-684.

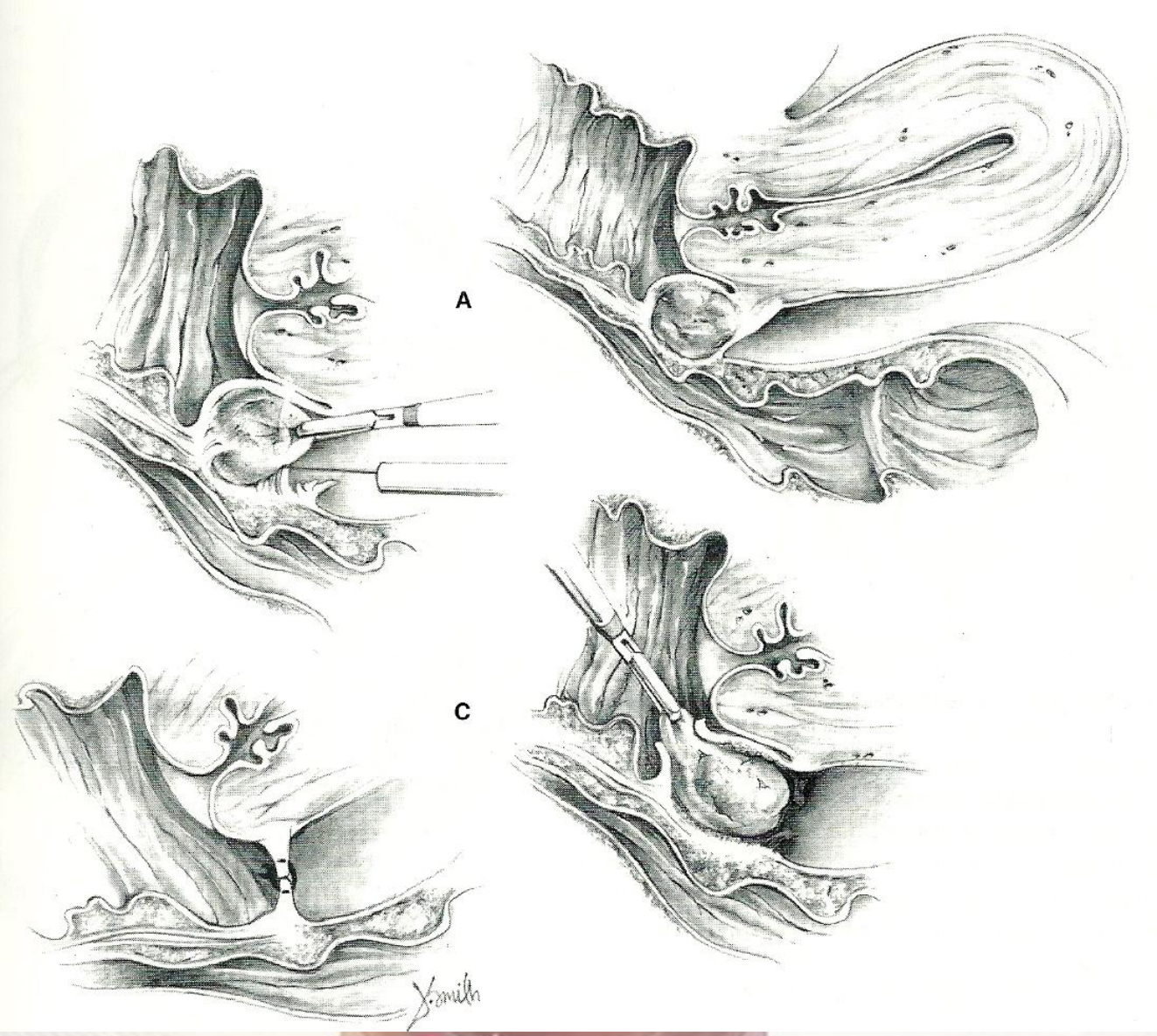

ROCK JOHN. Endometriosis. Ginecología Quirúrgica. TE LINDE. Novena Edición. Tomo I, capitulo 25. pág.. 645-684.

LAPAROTOMIA

- Se debe reservar para enfermedad avanzada.
- Cuando no se desea conservar la fertilidad.
- Tratamiento quirúrgico radical.

A health related quality-of-life instrument for symptomatic patientes with endometriosis: a validation study. Colwell HA et al. Am. J. Obstet Gynecol.1998.Jul; 179 (1): 47-55.

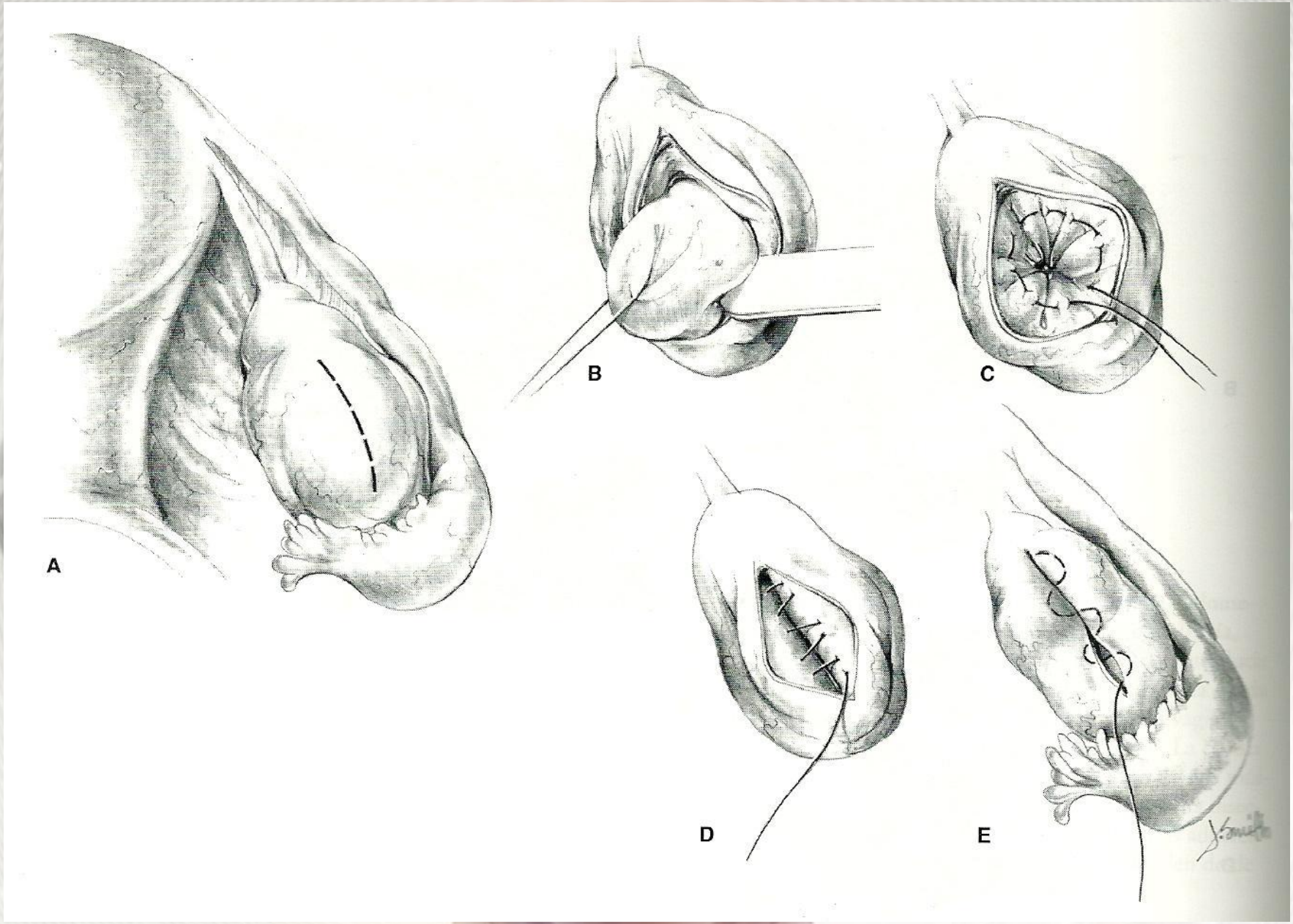

ROCK JOHN. Endometriosis. Ginecología Quirúrgica. TE LINDE. Novena Edición. Tomo I, capitulo 25. pág.. 645-684.

ABLACION LAPAROSCOPICA DE LOS NERVIOS UTERINOS

Ruggi en 1899

Sección transversal de ambos ligamentos uterosacros

La técnica controvertido

Preferiblemente Laser

Lichten y Col. En un estudio controlado doble ciego aleatorizado: NO mejoría del dolor pélvico.

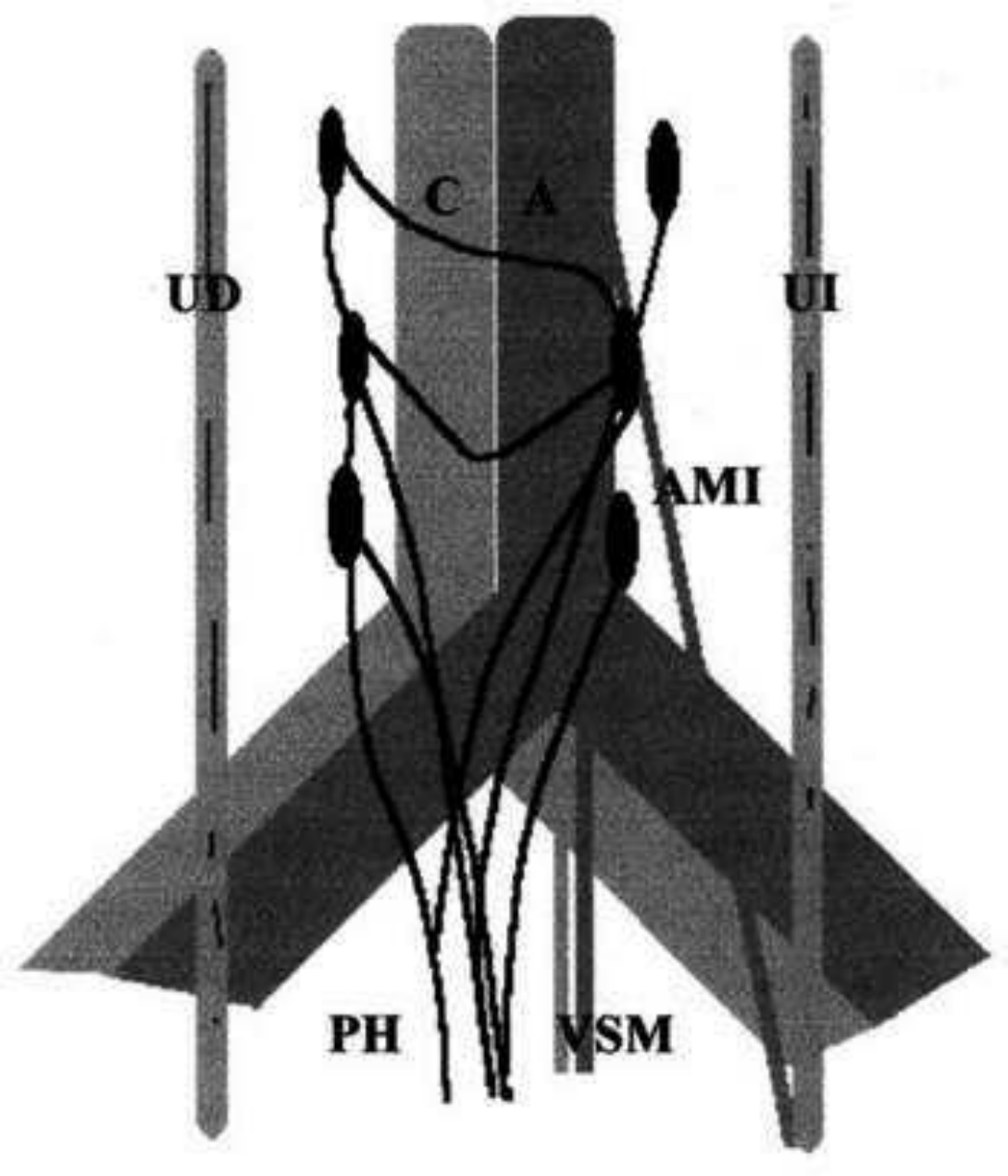
C
A
UD
UI
AMI
PH
VSM

NEURECTOMÌA PRESACRA

LUNA: laparoscopic uterosacral nerve ablation

Esta técnica tiene por objeto perturbar el plexo hipogástrico

Cochrane Review (agosto 2002): resultados de la cirugía laparoscópica, en endometriosis asociada con infertilidad: (112 pacientes)

Estudio prospectivo observacional: demostro que la neurolisis quimica laparoscopica presacra con fenol, produce reduccion del dolor pelvico y mejoria de la funcion sexual.

- Abierto o por laparoscopia
- Complicaciones: resequedad vaginal y constipación
- No mejoría de la fertilidad.

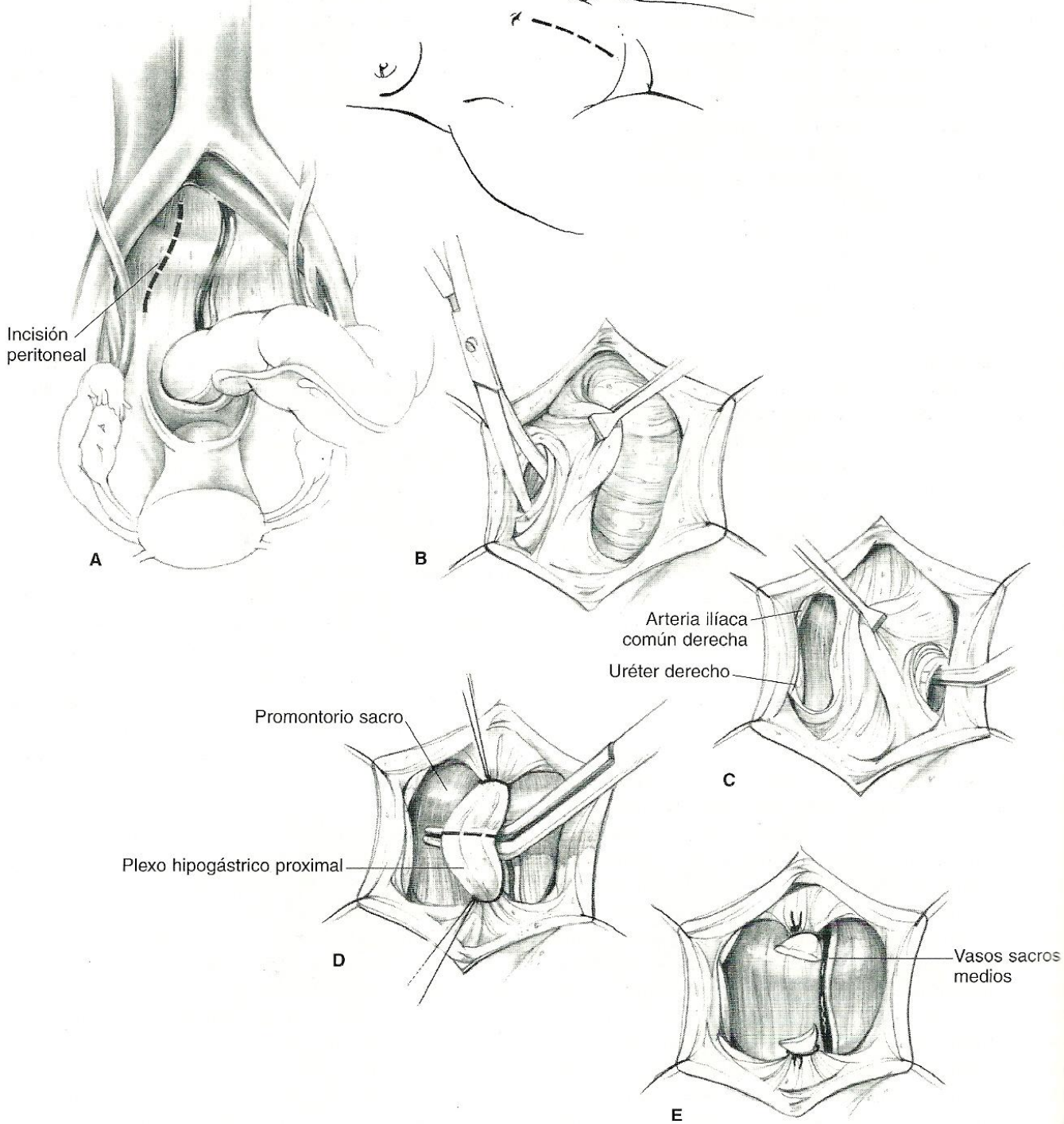
Incisión peritoneal
A
B
Arteria ilíaca común derecha
Uréter derecho
C
Promontorio sacro
Plexo hipogástrico proximal
D
Vasos sacros medios
E

HISTERECTOMIA CON O SIN OOFORECTOMIA

- Pacientes con paridad satisfecha y dolor severo con falla de tratamiento conservador

- Adenomiosis

- Ooforectomía sólo debe considerarse una vez que está claro que los ovarios son la causa del dolor pélvico

- Estudio kaplan - Meier

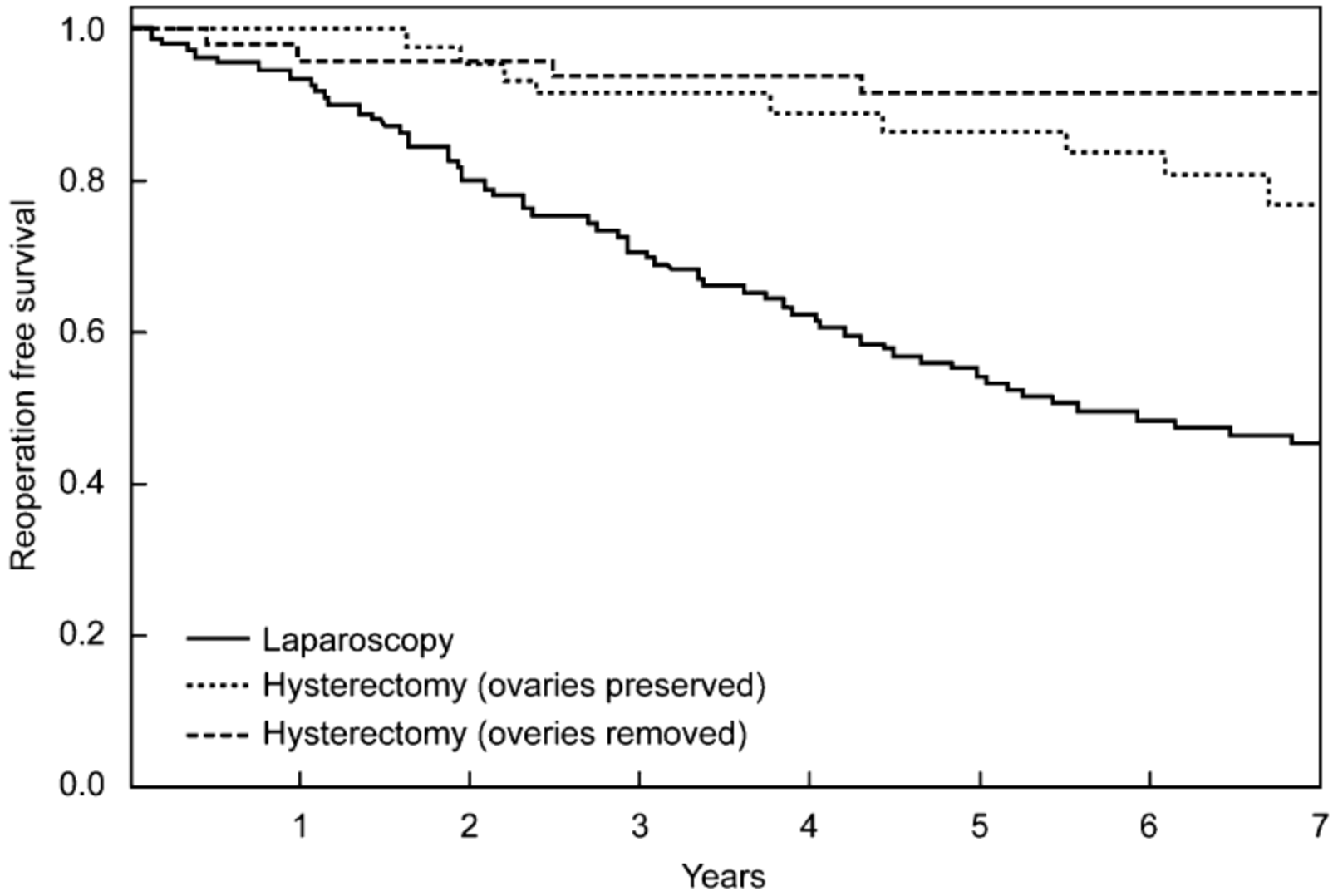

FIGURE 2. Reoperation free survival estimates are shown for groups defined by surgery type and ovary preservation. Abstracted from *Obstet Gynecol*. 2008;111(6):1285–1292.

TRATAMIENTO MEDICO

- PREOPERATORIO: reducción del tamaño y vascularidad de los implantes

- POSTOPERATORIO:
  - Erradicar implantes endometriósicos residuales y tratamiento de la enfermedad microscópica

- Ninguno demostró mejoría en la fertilidad futura

- Demoran la búsqueda del embarazo luego del tratamiento quirúrgico

ASRM Practice Committee, 2004

Treatment of Patients with Endometriosis

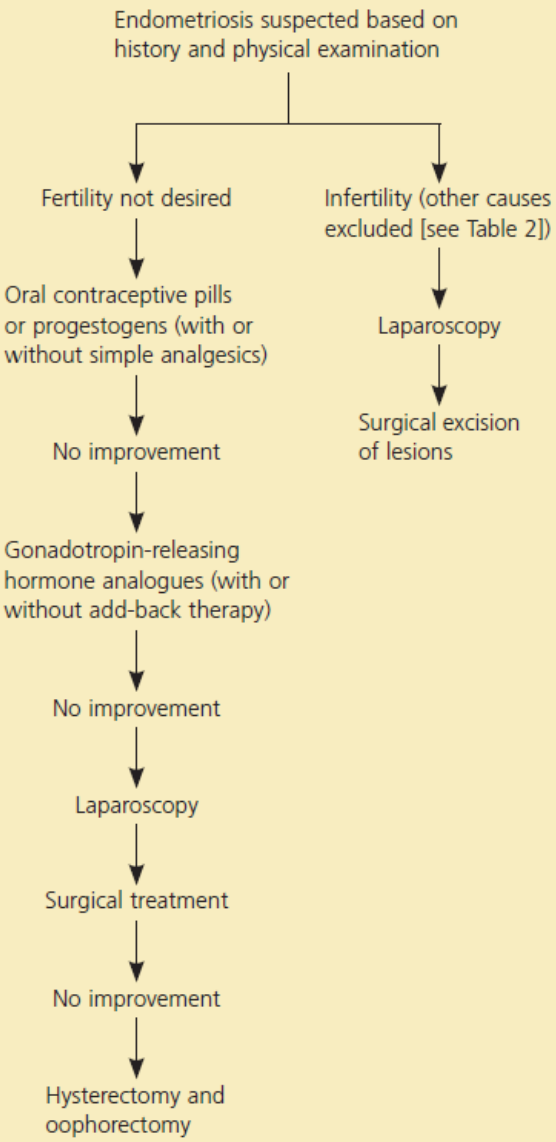

SORT: KEY RECOMMENDATIONS FOR PRACTICE

Clinical recommendation	*Evidence rating*	*References*
The preferred method for diagnosing endometriosis is direct visualization of lesions with histologic confirmation.	C	15
Danazol (Danocrine) may be used for pain relief in patients with endometriosis.	A	22
OCPs, progesterone-only OCPs, and medroxyprogesterone acetate (Provera) should be used as first-line therapies for treating pain associated with endometriosis.	A	24-26
Because gonadotropin-releasing hormone analogues provide equivalent pain relief as OCPs and progestogens with more side effects, they should be used only as second- or third-line agents.	A	27
Surgical ablation of endometrial deposits with or without laparoscopic uterine nerve ablation can be performed for pain relief.	B	30, 31
Laparoscopic surgery can be performed in women with subfertility and endometriosis.	B	32
Presacral neurectomy can be performed in women with midline abdominal pain from endometriosis.	B	31
Laparoscopic cystectomy is preferred over drainage for pain relief in women with endometriosis.	B	33

OCPs = oral contraceptive pills.

A = consistent, good-quality patient-oriented evidence; B = inconsistent or limited-quality patient-oriented evidence; C = consensus, disease-oriented evidence, usual practice, expert opinion, or case series. For information about the SORT evidence rating system, see page 542 or http://www.aafp.org/afpsort.xml.

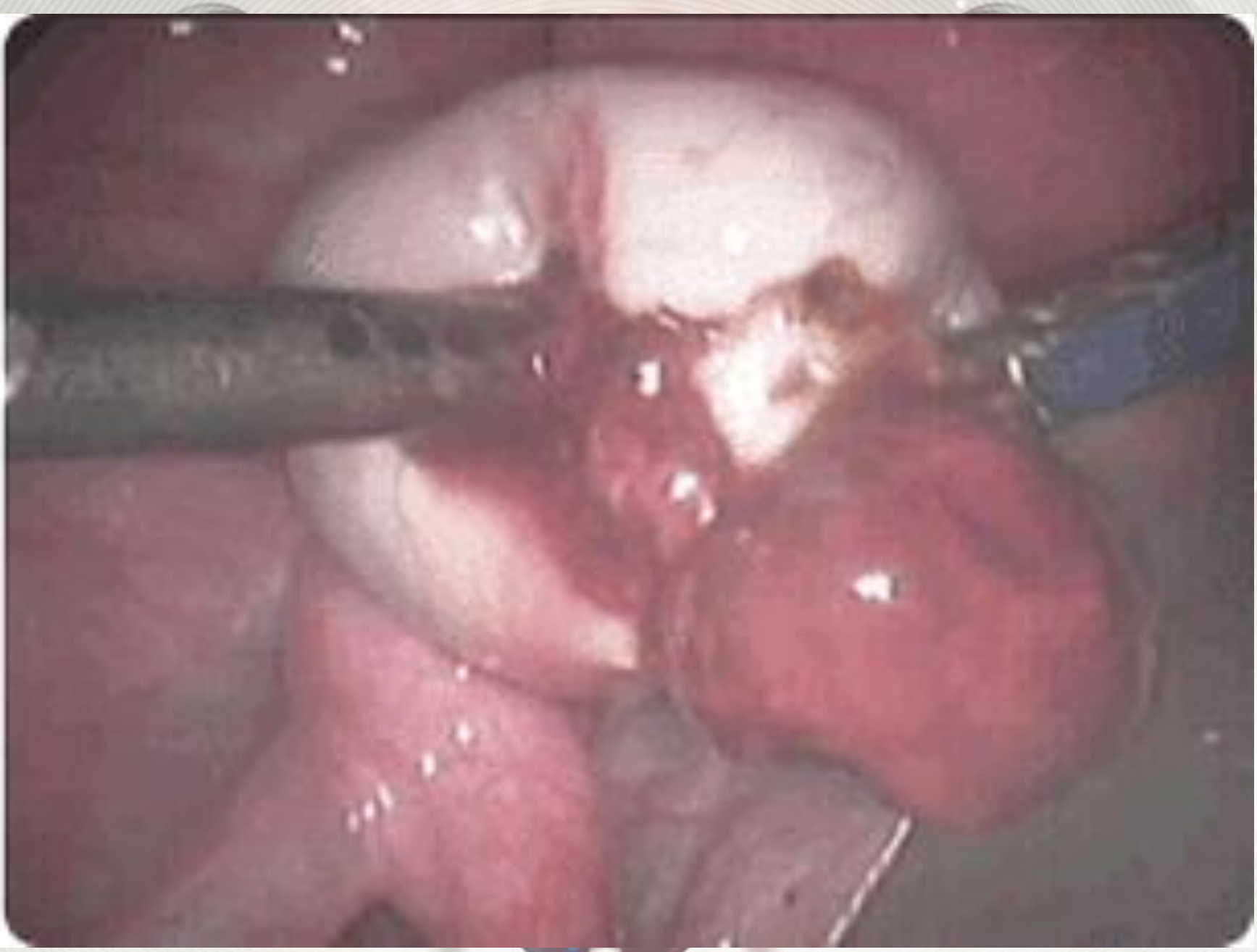

Surgical treatment

GPP	Depending upon the severity of disease found, ideal practice is to diagnose and remove endometriosis surgically at the same time, provided that pre-operative adequate consent has been obtained (Redwine and Wright, 2001; Abbott *et al.*, 2003; Chapron *et al.*, 2003b; Fedele *et al.*, 2004).

There are no data to justify hormonal treatment prior to surgery to improve the success of surgery (Muzii *et al.*, 1996).

A	Ablation of endometriotic lesions plus laparoscopic uterine nerve ablation (LUNA) in minimal–moderate disease reduces endometriosis-associated pain at 6 months compared to diagnostic laparoscopy; the smallest effect is seen in patients with minimal disease (Jacobson *et al.*, 2004a). However, there is no evidence that LUNA is a necessary component, as LUNA by itself has no effect on dysmenorrhoea associated with endometriosis (Vercellini *et al.*, 2003a).	Evidence level 1b

There are no data supporting the use of uterine suspension but, in certain cases, there may be a role for pre-sacral neurectomy (Soysal *et al.*, 2003).

GPP	Endometriosis-associated pain can be reduced by removing the entire lesions in severe and deeply infiltrating disease. If a hysterectomy is performed, bilateral salpingo-oophorectomy should also be considered (Namnoum *et al.*, 1995), provided that all visible endometriotic tissue is removed at the same time (Lefebvre *et al.*, 2002).

Post-operative treatment

A	Treatment with danazol or a GnRH agonist for 6 months after surgery reduces endometriosis-associated pain and delays recurrence at 12 and 24 months compared with placebo and expectant management. However, post-operative treatment with a COC is not effective (Telimaa *et al.*, 1987; Parazzini *et al.*, 1994; Hornstein *et al.*, 1997; Bianchi *et al.*, 1999; Morgante *et al.*, 1999; Vercellini *et al.*, 1999b; Muzii *et al.*, 2000; Busacca *et al.*, 2001).	Evidence level 1b

CLINICAL OBSTETRICS AND GYNECOLOGY
Volume 53, Number 2, 429–438
© 2010, Lippincott Williams & Wilkins

Endometriosis and Infertility

KRISTIN J. HOLOCH, MD and BRUCE A. LESSEY, MD, PHD
Department of Obstetrics and Gynecology, Greenville Hospital System, Greenville, South Carolina

Treatment of endometriosis-associated infertility in confirmed disease

Treatment of endometriotic lesions

Hormonal treatment

A	Suppression of ovarian function to improve fertility in minimal–mild endometriosis is not effective and should not be offered for this indication alone (Hughes *et al.*, 2004). There is no evidence of its effectiveness in more severe disease.	Evidence level 1a

Surgical treatment

A	Ablation of endometriotic lesions plus adhesiolysis to improve fertility in minimal–mild endometriosis is effective compared to diagnostic laparoscopy alone (Jacobson *et al.*, 2004b).	Evidence level 1a

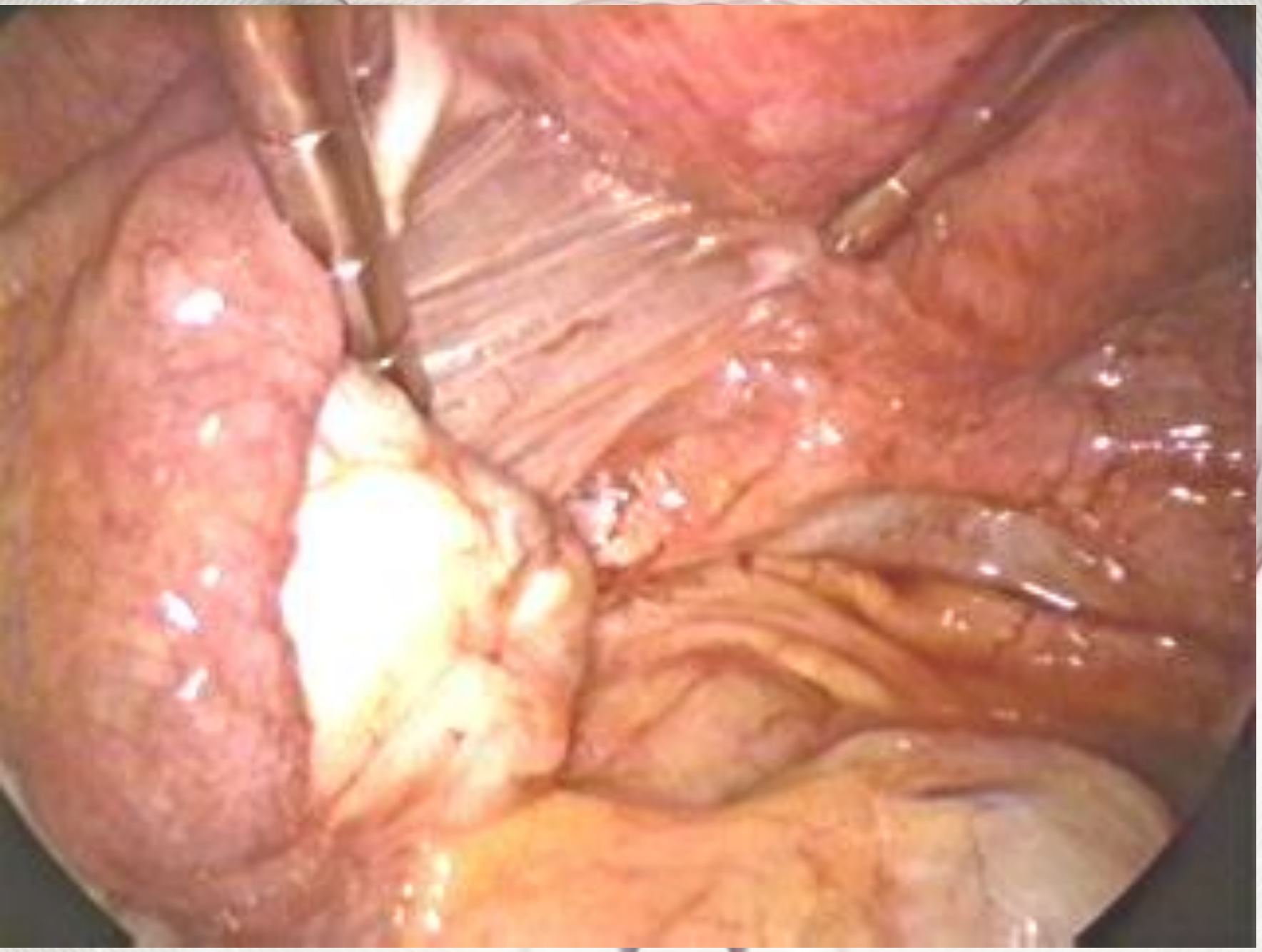

A	Laparoscopic cystectomy for ovarian endometriomas >4 cm diameter improves fertility compared to drainage and coagulation (Beretta *et al.*, 1998; Chapron *et al.*, 2002) Coagulation or laser vaporization of endometriomas without excision of the pseudo-capsule is associated with a significantly increased risk of cyst recurrence (Vercellini *et al.*, 2003b).	Evidence level 1b

Post-operative treatment

A	Treatment with danazol or a GnRH agonist after surgery does not improve fertility compared with expectant management (Parazzini *et al.*, 1994; Bianchi *et al.*, 1999; Vercellini *et al.*, 1999b; Busacca *et al.*, 2001).	Evidence level 1b

- El tratamiento quirúrgico de la paciente infértil con endometriosis mínima o leve es motivo de grandes controversias.

- Tasa acumulativa de embarazos a 5 años sin tratamiento en pacientes con endometriosis leve es de 90% vs 93% en mujeres sin la enfermedad

Cumulative pregnancy rates ininfertile women with endometriosisBadawy SZA et al. JReprod Med 1988;33:757-60.

Tabla 10-2. Tratamiento de la EDT	
Forma	**Tasas Emb. %**
Expectante (peritoneal)	6 - 50
Hormonal	
GnRHa	20 - 70
Danazol	23 - 68
Medroxiprogesterna	25 - 47
Gestrinone	33- 59
Cirugia	
Laparotomía (conservadora)	37-74
Laparoscopia	56-70
Reproducción asistida	
IIU	45-54
GIFT	25-41
IVF-ET	35-64

- HEMOSTASIA

- Esponjas de gelatina absorbible (Gelfoan)
- Colágeno microfibrilar (Avitene)
- **Coagulación Bipolar**
- Endocoagulaciòn o clips hemostáticos
- Lasers de fibra (KTP/532)

GRACIAS